

Automatic Detection of Elbow Abnormalities in X-ray Imagery

Mashal Afzal¹, M. Moazzam Jawaid², Rizwan Badar Baloch³, Sanam Narejo⁴

Department of Computer System Engineering
Mehran University of Engineering and Technology
Jamshoro, Pakistan

Abstract—Abnormality or deformity in any of the bone disrupts overall function of human skeleton. Hence, orthopedic abnormalities are common reasons for emergency department visits and elbow deformation is one of the common issue seen among emergency patients. Despite high frequency of elbow-related casualties, there is no standardized method for interpretation of digital X-rays. Accordingly, we have proposed a model for automatic deformation detection in elbow and connected forearm bones using Image Processing techniques. The X-ray images were preprocessed and the region of interest is segmented using Multi Class Probabilistic Segmentation in first step. Subsequently, multi-phase canny edge detector was used to highlight the edges and descriptive features were extracted to differentiate among normal and abnormal X-rays. On the basis of those features, three tests were performed to automatically trace deformities in different bones associated with elbow. The publically available Musculoskeletal Radiographs (MURA) dataset has been used in this research. Hence, 250 elbow X-rays from the dataset were investigated for geometrical shape distortions, crack, damage and extra-ordinary distance between the bones. Accordingly, the proposed method shows promising results in terms of 86.20% accuracy.

Keywords—Deformation detection; multi-class probabilistic segmentation; edge detection and geometrical shape detection

I. INTRODUCTION

In human skeleton which comprises 207 bones, every bone attains a very stimulating role and has same importance in entirety of skeleton. A minute abnormality or deformation in any of the bone can influence general structure of human skeleton.

The abnormality can occur in any bone such as leg, finger, femur, hand, rib cage, shoulder, chest, humerus and knee, etc. From the recent study, it is apparent that orthopedic abnormalities are one of the prevalent reason for emergency department visits [1]. Among these visits, elbow associated casualties are one of the common issues for the emergency visits. Some of the foremost reasons of elbow abnormalities are weight lifting, road accident, job involving repetitive hand moment, sports, trapped nerves, physical trainings, stiffness and arthritis.

In adults, the ration of elbow and forearm fractures is around eight to ten percent which are increasing steadily [2]. Over and above 1.7 billion people worldwide are effected with orthopedic abnormalities, which results in long-lasting, unbearable pain and disorders in human body [3].

For this growing rate of abnormalities, Medical image diagnosing tools are indispensable in this age [4]. One of the common pattern for abnormality diagnosing is X-ray which gives the shadow-like image as a result. Comparing with other image diagnosing methods, X-ray images are effective to use due to easy availability, inexpensiveness, harmlessness and high speed [5].

The digitization of medical imagery is an imperative trend now days. Despite high regularity of elbow-associated abnormalities, there isn't any standardized method available for interpretation of digital X-ray images [6]. This research, emphasis on digitizing deformation detection for elbow X-ray images Fig. 1.

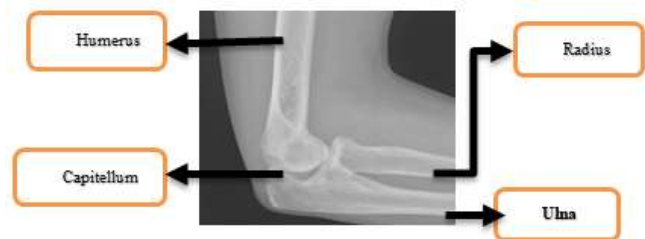

Fig. 1. Lateral View of Elbow X-ray Referring to Different Bones Present in Human Elbow [12].

Deformation or abnormality in elbow bone occurs in many ways depending on the number of joints and nature of the bone [7]. In this study, we will focus on categorizing elbow X-ray image as normal or abnormal by following the methodology discussed below in Section 3.

The work flow for this study comprises four more sections. The related work to diagnose abnormality in the bones of elbow and to wisely interpret X-ray images has been concisely presented in Section 2. Later on, in next two sections (3 and 4) we have presented the methodology followed to achieve our goal and the results based on numerous experiments. Furthermore, the conclusion of our study and the future work is presented in next section.

II. LITERATURE REVIEW

Elbow abnormalities can be detected through many ways using medical imaging but due to easy availability of X-ray images, this technique is widely used and suggested by the orthopedics [5]. Earlier, the deformation detection in elbow X-ray images has been performed manually but with the rise in

technology some methods have been proposed to digitally interpret the X-ray images which are discussed below.

The deformation in elbow X-ray images depends on the nature of bone as there are four bones involved in human elbow. The two bones radius and ulna which runs from forearm to elbow joint through capitellum which further joints these two bones with humerus bone that runs from elbow to shoulder. So, the deformation in any bone involved in elbow can effect multiple other bones too as they all are interconnected to form the skeleton.

In [8], the author presents the idea to detect abnormalities in capitellum, it is the major joint in between the other three bones involved in elbow. To resist the abnormality in other bones the deformation in capitellum needs to be diagnosed at initial stage. This study states that the capitellum fractures are minor and mostly ignored at emergency visits but these minor fractures cause major abnormality, if not treated properly. To detect the capitellum abnormality, the author suggests the idea to analyze the arc sign around circular shaped capitellum. The arc sign is the key point to differentiate between normal and deformed elbow X-ray. All the deformed X-ray images which include arc sign were further treated. After the treatment, the arc sign was not seen in the usual X-ray images. A very basic concept was suggested by the author however; this analysis was performed manually which didn't resolve the issue of digitally interpreting elbow X-ray images.

In [9], the author presents the idea to diagnose abnormality in humerus bone of elbow. A long bone running from shoulder to elbow with one end joined with capitellum. The ends of long bones are covered through a rubber type padding in human body called as cartilage. The discontinuity in between two cartilages at the ends of humerus bones direct towards geometrical shape deformation in elbow. To cover this problem, the author used canny edge detection method on humerus X-ray images to find sharp boundaries of humerus bone. On the resulting image, the parametric equation of straight line is used to detect straight line at the boundaries of humerus bone. The discontinuity or an angular curve between the lines was analyzed as geometrical shape deformation in humerus bone of elbow. This method was implemented on 48 X-ray images with 79.3% accuracy, however it only works for separate humerus X-rays and do not work if the other bones are involved in elbow X-ray image.

Another study has been proposed for the detection of fracture in radius and ulna bones using image segmentation techniques [10]. This study works for finding fracture in several long bones including femur, leg, radius and ulna. This study suggests to apply wiener filter to remove noise from images and then smoothing the images by using cumulative and probability distribution. Subsequently, image segmentation has been applied to get the region of interest which is followed by Edge detection method. Moreover, this study uses Hough transform to detect the straight lines to detect the fracture in similar manner as the author analyzed the fracture in previous study [9]. This algorithm detects fracture with 89.6% accuracy but the drawback for this study is similar as the previous that it only detects fracture in horizontal poses of X-ray images for different bones. Whenever the radius or

ulna bone is linked with capitellum, the algorithm fails to detect any deformation.

Another interesting study has been presented by the author which detects radial head fracture at the top of radius bone at the main joint capitellum [11]. Normally, there's a small rise at the joint when the X-ray is normal but in case of abnormality the rise disappears or appears geometrically disturbed. The author has presented very meaningful idea but this was also practiced manually on elbow X-ray images.

The main problem of the manual analysis of X-ray images could be solved by automating the fracture detection methods. Besides these studies, there are many other studies to interpret the elbow abnormalities by using different image modalities. Our study focuses on automating the interpretation of elbow X-ray images using certain techniques discussed in next section.

III. METHODOLOGY

In this portion, the proposed methodology is discussed to automatically detect the abnormality or any deformation in any bone of elbow. Three tests are proposed to check the elbow abnormality. If the X-ray image clears all the tests, it will be considered as normal X-ray image otherwise it will be classified as abnormal X-ray. The flowchart for the proposed approach is given below in Fig. 2.

A. Data Acquisition and Pre-Processing

The dataset used for the study is assembled from the website of Stanford ML group. Musculoskeletal Radiographs (MURA) is released by Stanford ML group [12]. This dataset contains X-ray images of different bones including elbow X-rays, hand X-rays, shoulder X-rays and finger X-rays, etc. 250 elbow X-rays are used for this study from the dataset including 190 normal and 60 abnormal X-rays. The X-ray images are preprocessed using image enhancement techniques and then resized and converted into gray scale images and finally processed for the next step.

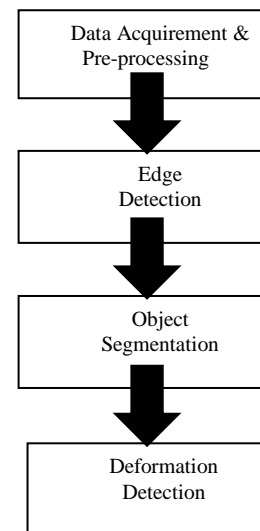


Fig. 2. Flowchart of Proposed Methodology.

B. Object Segmentation

The X-ray images contain background, flash and bone. To get the region of interest i.e. elbow bone, multi class probabilistic segmentation is applied on the preprocessed X-ray images [13]. Multi class probabilistic segmentation works by computing prior probabilities for each pixel of image and discovers the evidence of the similarity of the pixel with the next one. On the basis of the evidence, the posterior probabilities are calculated and the pixels are divided into multiple classes. The result of three class probabilistic segmentation as there are three regions in the images is shown in Fig. 3.

For class 1, all the pixels for background consuming same values are enhanced as shown in Fig. 3(b). For the remaining area, the posterior probabilities are recomputed and the result of class 2 is shown below in Fig. 3(c).

As a result of class 3, the pixels having same values for bone are highlighted as shown in Fig. 3(d). With the help of three class probabilistic segmentation, the bone is extracted from the X-ray image and further processed in next step.

C. Edge Detection

On the segmented image, canny edge detection method is applied. The multi-phase edge detector is applied to highlight wide-ranging edges and boundaries on the resulting X-ray [14]. With the help of canny method, the boundaries of the elbow bone are highlighted as shown below in Fig. 4(b).

The edge highlighted image is further processed in next step where several features are extracted to differentiate between normal and abnormal elbow X-ray image.

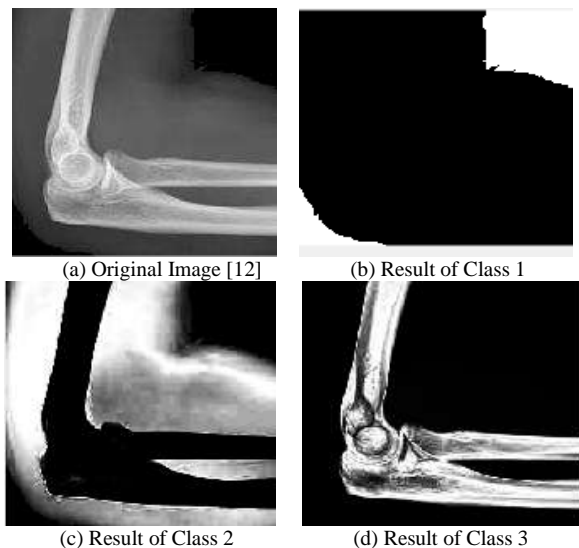


Fig. 3. Probabilistic Segmentation for Three Regions. (a) Indicates the Original Elbow X-ray Image. (b) Indicates the Result for Segmentation of First Class which Highlights the Pixels of Background. (c) Shows the Result of Second Class Segmentation in which the Pixels Involved in Flash are highlighted. (d) shows the region of interest as a result of third class Segmentation in which the Bone in the X-ray Image is Highlighted.

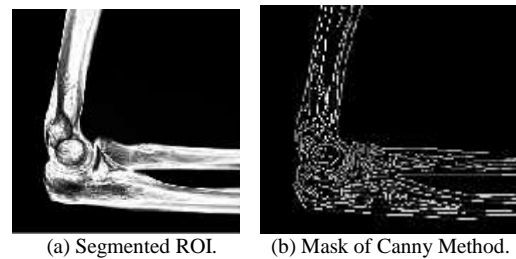


Fig. 4. Edge Perceived Bone. (a) Indicates the Segmented Bone from Actual X-ray Image. (b) Shows the Edge Detected Image through Canny Method.

D. Deformation Detection

The deformation in any bone of elbow is highlighted in this step. So, this step is very imperative among all steps of methodology. On the basis of possible reasons of deformation in elbow X-ray that has been learnt from literature, three tests are suggested to classify the images to normal and abnormal classes. The three suggested tests to differentiate in between normal and abnormal X-rays are enlisted below.

- Test: 01 for Capitellum Deformation Detection.
- Test: 02 for Radial or Ulnar Fracture Recognition.
- Test: 03 for Geometrical Shape Abnormality Identification.

1) *Capitellum deformation detection*: The very first test is related with capitellum that is the smooth, rounded eminence and major joint which holds overall structure of elbow, the minor deformation at this joint will effect overall erection of elbow [15]. To detect deformation in capitellum, Circular Hough transform is applied to identify the circular shaped capitellum [16]. CHT detects the capitellum using the range of pixels for radius as 16 ± 2 pixels for this test. This range is acknowledged by practicing on various normal X-rays in which capitellum is not dislocated or distorted. The result of this process is shown below in Fig. 5.

The capitellum is located back on the original X-ray image as illustrated in 5(b). All the elbow X-rays which intent capitellum will be categorized as normal at this stage and further processed through other tests. All those X-rays which didn't reflect capitellum will be categorized as abnormal as the deformation or dislocation of capitellum is a major sign of abnormality.

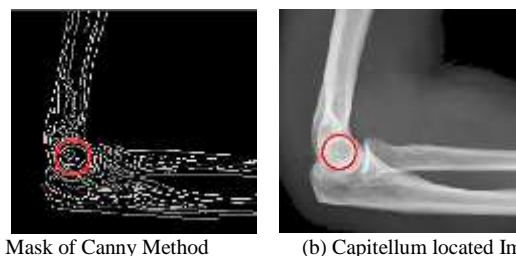


Fig. 5. Capitellum Detection on the X-ray Image of Elbow. (a) Indicates the Circular Shaped Capitellum Detection on Canny Mask. (b) Indicates the Capitellum Visualization on Actual X-ray Image.

2) *Radial or ulnar fracture recognition:* This test analyzes those elbow X-rays which clear capitellum based test and categorized as normal. For further diagnosing these two bones which runs from elbow to forearm, the center points of radius and ulna bones are identified by checking intensity at the end of these bones and using peak analysis as shown below in Fig. 6(b).

After getting the centerpoints as shown in Fig. 6(c) below, the centerlines are generated from these points towards capitellum, these center points will serve as ending points to check intensity and the starting points are detected by placing a straight line at the maximum position of capitellum using basic parametric equation of line as shown in Fig. 6(d).

A number of points are located in between these points to check the intensity at the center of bones to detect any fracture in radius and ulna as shown in Fig. 6(e).

There are two possibilities of deformation in forearm bones as two bones are joint with capitellum.

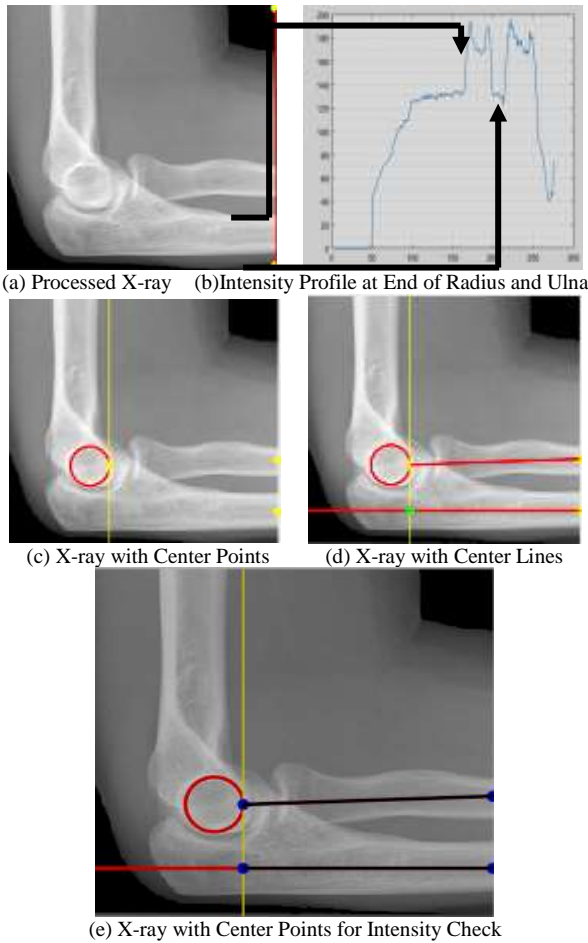


Fig. 6. Processed X-ray for Radial or Ulnar Distortion Detection. (a) Shows the X-ray Image Processed Till the end of Radius and Ulna Bones to Check Intensity. (b) Shows the Intensity Profile at the End of Both of the Bones. (c) Shows the X-ray with Center Points Detection at the End of Ulna and Radius. (d) Shows the Processed X-ray with Center Lines in Middle of Forearm Bones. (e) Shows X-ray with Multiple Points at the Center Lines to Check any Fracture.

a) *Normality detection in radius bone:* The intensity is checked at each point in the center of normal radius bone as shown below in Fig. 7(a). The arrow points towards direction of intensity profile.

Due to shadow on the X-ray images at capitellum there is a little rise in intensity in Fig. 7(b). Except that, the intensity has same patten for normal radius bone.

b) *Deformity detection in radius bone:* The same procedure is applied on abnormal bone as shown in Fig. 8.

As moving far from the circular shaped capitellum, there is a fracture in the bone of radius which is detected in intensity profile as disturbance in intensity.

c) *Normality detection in ulna bone:* For normal lower bone (ulna), the same method is applied to check any deformation and the results are shown below in Fig. 9.

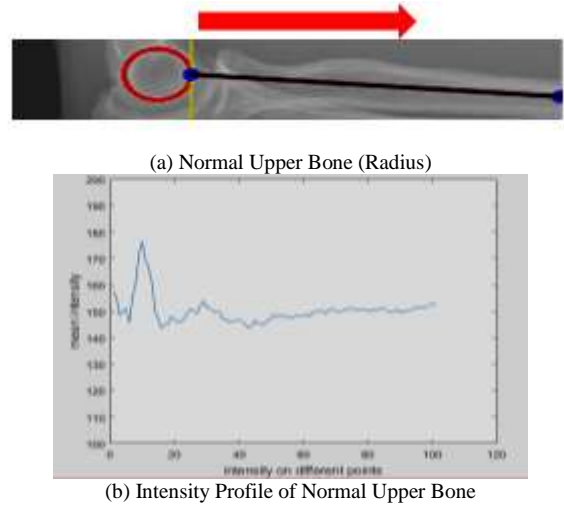


Fig. 7. Deformation Detection in Normal Upper Bone (Radius). (a) Shows the Usual Radius Bone with Multiple Points at Centerline to Check Intensity. (b) Demonstrates Intensity Profile of Usual Radius Bone.

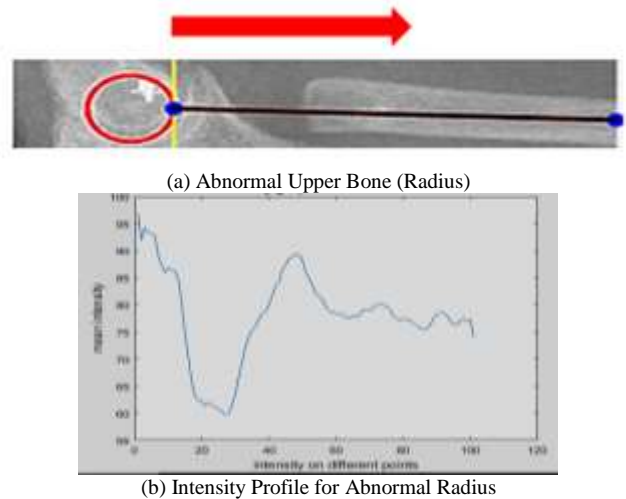


Fig. 8. Deformation Detection in Abnormal Radius. (a) Indicates the Abnormal Radius Bone with Multiple Points at Centerline to Check Intensity. (b) Shows Intensity Profile for Abnormal Upper Bone (Radius).

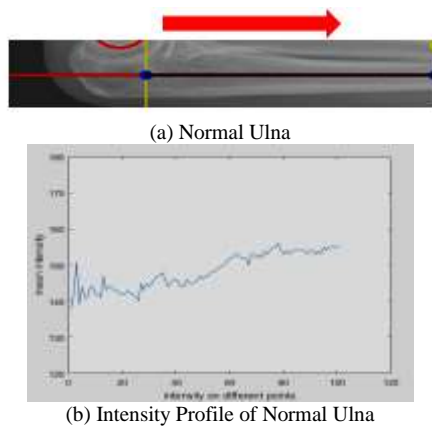


Fig. 9. Deformation Detection in Normal Ulna. (a) Indicates the Normal Bone with Multiple Points at Centerline to Check Intensity. (b) Indicates Intensity Profile of Normal Ulna.

The intensity has almost same pattern for normal radius bone as there is no any fracture in the bone when checked by moving away from capitellum.

d) Deformity detection in ulna: The same process is practiced on fractured ulna and the intensity has a different pattern as compared with normal bone, the results are shown below in Fig. 10.

The intensity pattern for abnormal bone is totally different from the normal one as there is drop in intensity due to fracture in ulna bone as shown above in Fig. 10(b).

All the elbow X-rays having fracture in radius and ulna bone will be categorized as abnormal by this test and the ones categorized as normal will be further processed to check deformation, if any.

3) Geometrical shape abnormality identification: The last test will analyze those elbow X-rays which didn't have any visible fracture but still they are abnormal. This is possible when the bones are overlapped or displaced. To detect this type of abnormality, all the X-rays which intent capitellum are further processed by selecting the region of interest for this test as shown in Fig. 11.

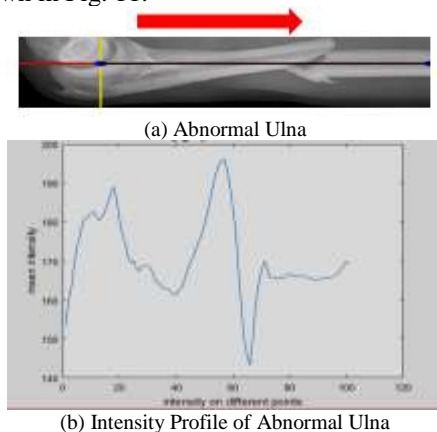


Fig. 10. Deformation Detection in Abnormal Bone. (a) Indicates the Abnormal Ulna with Multiple Points at Centerline to Check Intensity. (b) Shows Intensity Profile of Abnormal Ulna Bone.

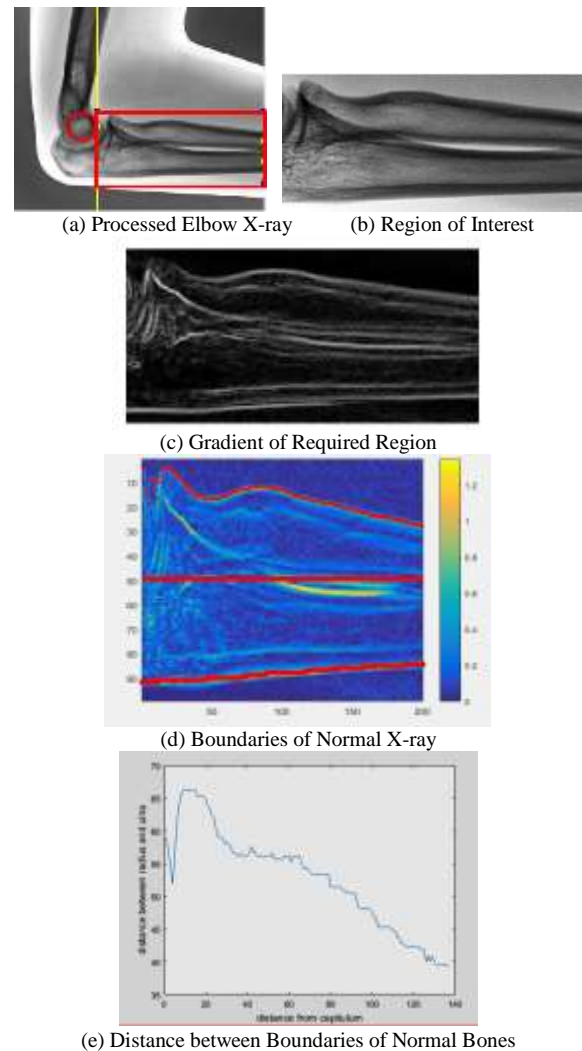


Fig. 11. Geometrical Shape of Normal Bone. (a) Shows the Processed Elbow X-ray to get the Required Region. (b) Shows the Required Region to Detect the Abnormality in Bones. (c) Shows the Output of Image Gradient. (d) Shows the Colored Version of Gradient Output with Boundaries of Normal Bones. (e) Indicates the Distance between Normal Radius and Ulna Bone.

Image gradient [17] is applied on the selected region to measure the change of intensity as shown in Fig. 11(c).

For better visualization, color map is applied to the output of gradient and the region is split into two parts. Using peak analysis, local maxima is detected at every point to get the margin of bones as shown in Fig. 11(d).

Subsequently, the distance among normal upper (radius) and lower (ulna) bone is calculated and the significant pattern is examined in most of the normal images as shown in Fig. 11(e).

When the similar pattern is applied on abnormal X-ray with no visible deformation, the significant pattern analyzed in many normal X-rays isn't found which can be seen in Fig. 12(b).

Any X-ray which clears these three tests will be considered as normal elbow X-ray. A number of X-rays are analyzed and the cumulative results is shown in next section.

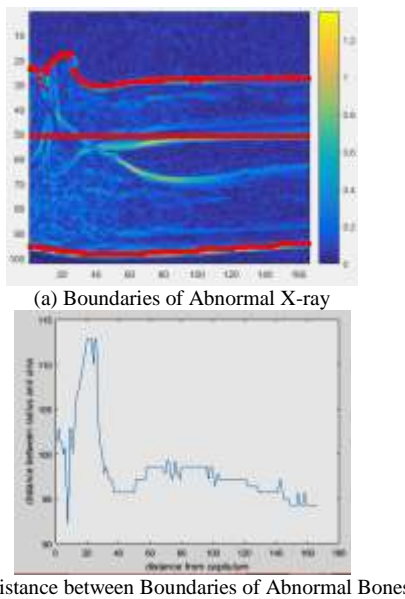


Fig. 12. Geometrical Shape of Abnormal Bones. (a) Shows the Image with Boundaries of Abnormal Bones (Radius and Ulna). (b) Shows the Distance of Abnormal Bones.

IV. RESULT AND DISCUSSION

The three tests are suggested to automatically detect any deformation in elbow and connected bones. From the dataset, 250 elbow X-rays are processed for this research and has been checked by all three tests.

A. Result for Capitellum based Test-01

All of the 250 images are analyzed through this test to detect the capitellum as it is the major sign for normality and abnormality detection. All those X-rays which didn't reflect capitellum are categorized as abnormal X-rays and the ones that clears this test are further processed by other two tests to check any likelihood of deformation.

Amongst 250 processed elbow X-rays, 190 X-rays are standard (normal) and 60 X-rays are deformed (abnormal). The capitellum based test correctly interpreted 170 normal X-rays and 53 abnormal X-rays with the accuracy of 89.2% as shown below in Fig. 13(a).

B. Result for Radial and Ulnar Fracture Test-02

All 223 X-rays that clears the previous test are further processed by this test. To detect fracture in radius and ulna bones, this test results in correctly analyzing 165 out of 170 normal and 25 out of 53 abnormal X-rays with the accuracy of 85.2% as shown below in Fig. 13(b).

C. Result of Geometrical Shape based Test-03

To detect any geometrical shape deformation, this test also analyzes those X-rays which cleared capitellum based test. 150 out of 170 X-rays are categorized as normal and 31 out of 53 as abnormal. This test results in accuracy of 81.2% as shown below in Fig. 13(c).

The overall accuracy of all the suggested tests for this study is observed as 86.2%.

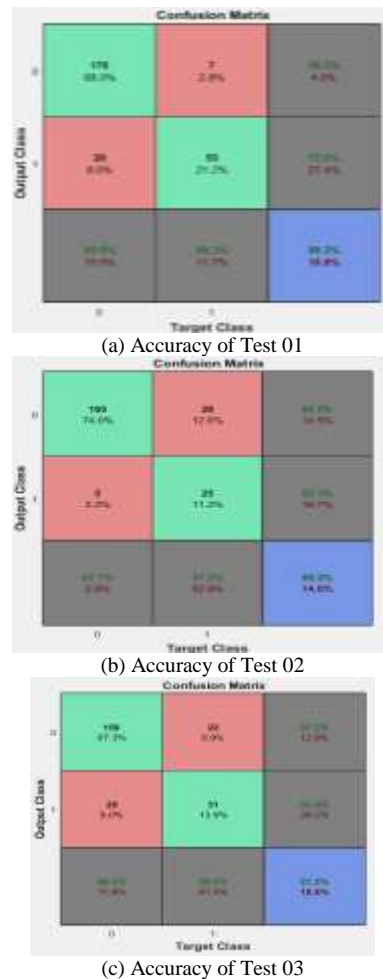


Fig. 13. Accuracy of suggested Test to Automatically Detect Deformation. (a) Shows the Accuracy of Capitellum based Test 01. (b) Shows the Accuracy of Radial and Ulnar Fracture Detection Test 02. (c) Shows the Accuracy for Test 03 related with Geometrical Shape based Deformation Detection.

V. CONCLUSION AND FUTURE WORK

In this study, a stimulating task to detect abnormalities of the bones in elbow X-ray images using computed approaches has been completed. 250 X-ray images from MURA dataset has been scrutinized for this process and the deformation in elbow X-ray images using computer based methods is detected centered on 3 Tests. The accuracy of proposed solution has been achieved around 86.2%.

Computer assisted techniques for finding deformation of bones in X-ray images will minimize human efforts and dependency which is the main problem in current time domain. Depending on those X-ray images which failed under these three tests, more features can be identified on the basis of edges and angular distance in between connected bones and the accuracy can be further improved.

REFERENCES

[1] Kozaci N, AyMO, AkçimenM, Turhan G, SasmazMI, Turhan S, et al. Evaluation of the effectiveness of bedside point-of-care ultrasound in the diagnosis and management of distal radius fractures. Am J Emerg Med 2015, 33(1):67-71.

- [2] J. C. McGinley, N. Roach, B. C. Hopgood, and S. H. Kozin, "Nondisplaced elbow fractures: A commonly occurring and difficult diagnosis," *Am. J. Emerg. Med.*, vol. 24, no. 5, pp. 560–566, 2006.
- [3] P. Rajpurkar et al., "MURA: Large Dataset for Abnormality Detection in Musculoskeletal Radiographs," no. Midl 2018, pp. 1–10, 2017.
- [4] M. R. Zare, A. Mueen, W. C. Seng, and M. H. Awedh, "Combined feature extraction on medical x-ray images," *Proc. - 3rd Int. Conf. Comput. Intell. Commun. Syst. Networks, CICSyN 2011*, pp. 264–268, 2011.
- [5] American Cancer Society, Imaging (radiology) tests, 2013. Accessed on: August 2020. [Online]. Available: http://www.cancer.org/acs/groups/cid/documents/web_content/003177
- [6] S. M. Kengyelics, L. A. Treadgold, and A. G. Davies, "X-ray system simulation software tools for radiology and radiography education," *Comput. Biol. Med.*, vol. 93, no. July 2017, pp. 175–183, 2018.
- [7] Y. Zhou et al., "Computer-Aided Detection (CADx) for Plastic Deformation Fractures in Pediatric Forearm," *Comput. Biol. Med.*, vol. 78, pp. 120–125, 2016.
- [8] Suresh, S.S., 2009. Type 4 capitellum fractures: Diagnosis and treatment strategies. *Indian journal of orthopaedics*, 43(3), p.286.
- [9] Kurniawan, S.F., PUTRA, D., GEDE, I.K. and SUDANA, A.K.O., 2014. BONE FRACTURE DETECTION USING OPENCV. *Journal of Theoretical & Applied Information Technology*, 64(1).
- [10] Kaur, T. and Garg, A., 2016. Bone Fraction Detection using Image Segmentation. *International Journal of Engineering Trends and Technology (IJETT)*, 36(2), pp.82-87.
- [11] Kim, H.T., Can, L.V., Ahn, T.Y. and Kim, I.H., 2017. Analysis of Radiographic Parameters of the Forearm in Traumatic Radial Head Dislocation. *Clinics in orthopedic surgery*, 9(4), pp.521-528.
- [12] Rajpurkar, P., Irvin, J., Bagul, A., Ding, D., Duan, T., Mehta, H., Yang, B., Zhu, K., Laird, D., Ball, R.L. and Langlotz, C., 2017. Mura: Large dataset for abnormality detection in musculoskeletal radiographs. arXiv preprint arXiv:1712.06957.
- [13] Bishop, C.M., 2006. Pattern recognition and machine learning. Springer Science+ Business Media.
- [14] Li, J. and Ding, S., 2011, August. A research on improved canny edge detection algorithm. In *International Conference on Applied Informatics and Communication* (pp. 102-108). Springer, Berlin, Heidelberg.
- [15] Hawks, J. 2019. Humerus. [online] john hawks weblog. Available from: <http://johnhawks.net/explainer/laboratory/humerus.html> [Accessed 17th Jul. 2019].
- [16] Djekoune, A.O., Messaoudi, K. and Belhocine, M., 2016. Incremental Hough transform: a new method for circle detection. In *Computational Intelligence* (pp. 3-22). Springer, Cham.
- [17] Saif, J.A., Hammad, M.H. and Alqubati, I.A., 2016. Gradient based image edge detection. *International Journal of Engineering and Technology*, 8(3), p.153.